




KEXOT Oct 2015/ N.P.

HIP ARTHROSCOPY – CYPRUS EXPERIENCE

25 HIPS (2009 -2014)

↓


20 Cases for FAI



↓

5 Cases for:

- Removal of loose bodies (synovial Chondromatosis, old Perthes etc)
- Release of Psoas tendon in a painful THR
- Debridement and Microfracture technique for acetabular bone cyst
- Biopsy of acetabular neoplastic bone lesion




2

KEXOT Oct 2015/ N.P.

FEMOROACETABULAR IMPINGEMENT

- ✗ Diagnosis was suspected on :
 - ✗ → Patient's History
 - ✗ → Clinical Examination
- ✗ Diagnosis was confirmed by:
 - ✗ → Radiographic Examination






3

KEXOT Oct 2015/ N.P.

FAI - DIAGNOSIS

- ✗ Patients History
- ✗ (Pain in sitting position very frequent symptom)
- ✗ C-Sign





4

KEXOT Oct 2015/ N.P.

FAI- DIAGNOSIS

- ✗ → Clinical Examination
- ✗ Most Important :
 - ✗ Log Roll Test
 - ✗ Pain with Full Flexion in supine position
 - ✗ Pain with internal Rotation
 - ✗ Impingement Test (sensitive but not specific)
 - ✗ Localized tenderness on hip joint
- ✗ (To exclude any other extra articular source of pain)






5

KEXOT Oct 2015/ N.P.

FAI - RADIOGRAPHIC EXAMINATION

- ✗ True AP- Pelvic view








6

KEXOT Oct 2015/ N.P.

FAI - RADIOGRAPHIC EXAMINATION

× **Modified Lateral or frog position view**









KEXOT Oct 2015/ N.P.

FAI - RADIOGRAPHIC EXAMINATION

× **Faux-Profil view**

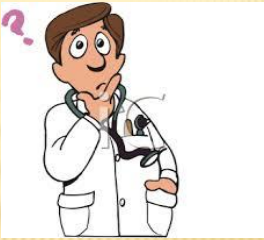
Anterior Center Edge Angle:
Less 25° → anterior under coverage






KEXOT Oct 2015/ N.P.

X-RAYS EVALUATION




KEXOT Oct 2015/ N.P.




X-RAYS EVALUATION

Lateral Center Edge Angle
Normal: 25°-40°

Less 25° → Under coverage
Dysplastic hip

More 40° → Over coverage
Pincher FAI



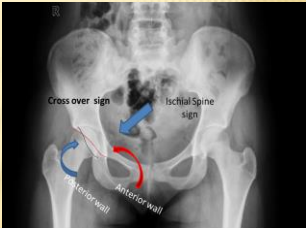










KEXOT Oct 2015/ N.P.

X-RAYS EVALUATION

Cross over sign: → Over coverage

Cross over sign + Ischial sign
→ Retroverted Hip














KEXOT Oct 2015/ N.P.

X-RAYS EVALUATION

Alpha Angle:
Sign of Head Sphericity
And Head-Neck Offset

Normal : Up to 50°
Values > 50° → Abnormal
→ CAM FAI

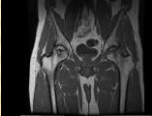


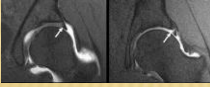

KEXOT Oct 2015/ N.P.

MRI EVALUATION

- × **Role of MRI in FAI** → Not diagnostic/supporting
 - To exclude other pathologies (AVN, Transient Osteoporosis, etc)




- **Role of MRI-Arthrogram** → Labrum Tear ??
 - Chondral Lesions ??

KEXOT Oct 2015/ N.P.

FAI - CYPRUS EXPERIENCE

- × **20 patients** → 15 male / 5 female
 - Age: 26-55 → mean age 38,6
 - 12 Left / 8 Right Hips




14

KEXOT Oct 2015/ N.P.



FAI - CYPRUS EXPERIENCE

- × **Pathology:**
- × **Pincher Type: 2** → Pincher Correction, (Irreparable Labrum) Debridement and Smoothing of Labrum
- **Cam Type: 12** → Cam Correction in all patients Debridement and Smoothing of Labrum In 3
- **Mixed Type: 6** → All with Labrum tear Correction of Pincher and Cam Deformity with additional Labrum Repair In 4 and Labrum Debridement/smoothing In 2



15

KEXOT Oct 2015/ N.P.


16

KEXOT Oct 2015/ N.P.

PINCHER CORRECTION- LABRUM REPAIR



Pincher Correction
Labrum Repair



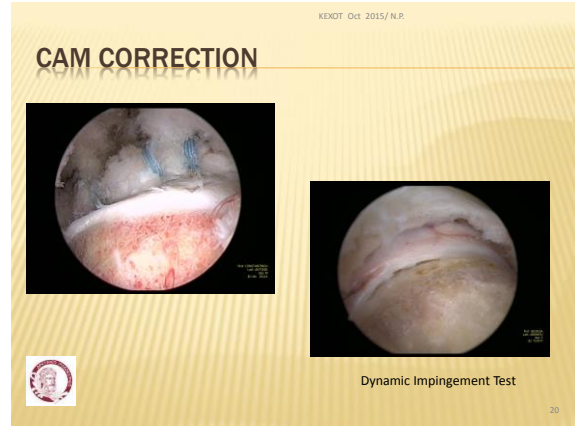
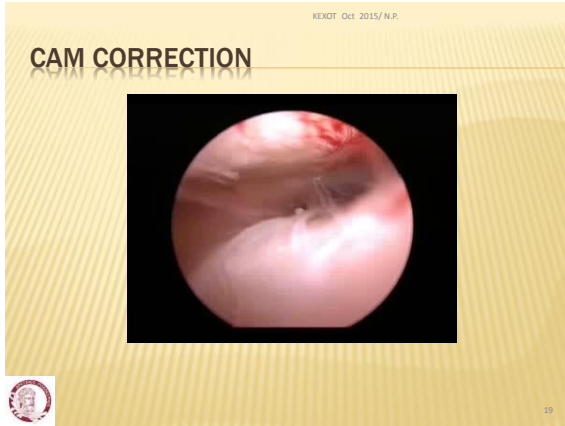17

KEXOT Oct 2015/ N.P.

PINCHER CORRECTION- LABRUM REPAIR






18



KEXOT Oct 2015/ N.P.

POST OP REGIME

- ✘ Indomethacin for 2/52,
- ✘ Thrombosis Prophylaxis
- ✘ Labrum Repair → NWB x 6/52
 - Avoid deep flexion X 3-4 /12
 - Return to sports after 5-6/12
- Cam Correction → PWB x 4-6/52
 - Return to sports after 5-6/12

21

KEXOT Oct 2015/ N.P.

FAI-ARTHROSCOPIC TREATMENT

- ✘ **Patients Evaluation:**
 - ✘ **1. Hip Outcome Score (HOS)** (self-questioner concerning Activity of Daily Living and Sports)
 - **2. International Hip Outcome Tool (short version IHOT 12)** (Self-questioner about daily activities ,functionality and Sports)

Evaluation : Preop/ Postop in 6 months




22

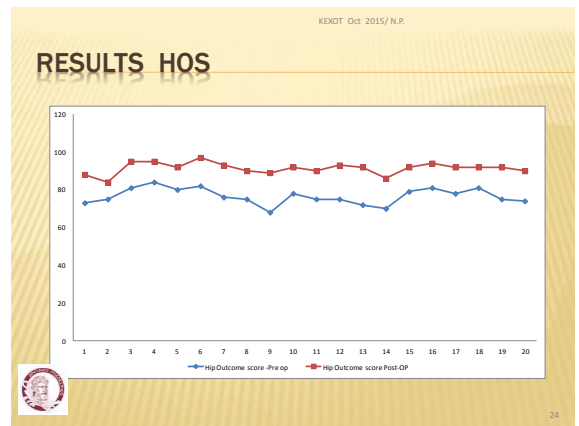
KEXOT Oct 2015/ N.P.

RESULTS

- ✘ **HOS** → Preop mean score: 76,6 out of 100
 - Postop mean score: 91,4 out of 100
- IHOT 12** → Preop mean score: 71,3 out of 100
 - Postop mean score: 88,8 out of 100

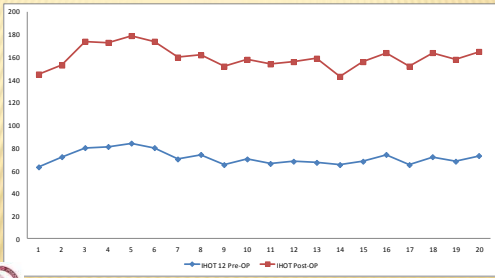


23



KEXOT Oct 2015/ N.P.

RESULTS IHOT 12



25

KEXOT Oct 2015/ N.P.



THANK YOU

www.papaloucasn.com



26